

# Pregnancy and live birth after focused ultrasound surgery for symptomatic focal adenomyosis: a case report

J.Rabinovici<sup>1,2,5</sup>, Y.Inbar<sup>2,3</sup>, S.C.Eylon<sup>1,2</sup>, E.Schiff<sup>1,2</sup>, A.Hananel<sup>4</sup> and D.Freundlich<sup>4</sup>

<sup>1</sup>Department of Obstetrics and Gynecology, Sheba Medical Center, Tel HaShomer, <sup>2</sup>Sackler School of Medicine, Tel-Aviv University, Ramat Aviv, <sup>3</sup>Department of Radiology, FUS Treatment Center, Sheba Medical Center, Tel HaShomer and

<sup>4</sup>InSightec Image Guided Treatments Ltd., Tirat Carmel, Israel

<sup>5</sup>To whom correspondence should be addressed at: Department of Obstetrics and Gynecology, Sheba Medical Center, Tel Hashomer 52621, Israel. E-mail: yaronr@post.tau.ac.il

**Adenomyosis is a benign disease whose symptoms mimic those of uterine leiomyoma. Hysterectomy is the treatment of choice; conservative surgery is difficult to perform and can damage the uterine structural integrity. We report the case of a 36-year-old woman who had difficulty conceiving because of profuse menometrorrhagia. An 84 cm<sup>3</sup> uterine tumour was diagnosed on ultrasonography as leiomyoma, and conservative myomectomy was planned. Magnetic resonance imaging (MRI) corrected the diagnosis to focal adenomyosis. Magnetic resonance-guided focused ultrasound surgery (MRgFUS) destroyed a significant part of the tumour. Following an uncomplicated MRgFUS treatment, a non-perfused volume of 33 cm<sup>3</sup> was measured. At 6 weeks, the patient experienced a significant reduction in menometrorrhagia and a marked decrease in tumour size (about 50%). She conceived spontaneously and, after an uneventful pregnancy, gave birth at term to a healthy infant via normal vaginal delivery. No structural uterine abnormality was detected after her delivery. This report highlights the difficult diagnosis and new therapeutic considerations of adenomyosis. MRgFUS seems to have the potential to precisely and effectively treat focal adenomyosis without damage to surrounding healthy myometrium, allowing for normal reproduction. Further studies are needed to assess the overall safety and long-term effectiveness of MRgFUS for the non-invasive treatment of adenomyosis.**

*Key words:* adenomyosis/focused ultrasound surgery/leiomyoma/pregnancy/uterine tumours

## Introduction

Adenomyosis is a common benign gynaecological disorder affecting premenopausal women, which is characterized by the growth of ectopic endometrial glands and stroma deep within the myometrium (Ota *et al.*, 1998; Byun *et al.*, 1999).

Symptoms of adenomyosis include menorrhagia, dysmenorrhea and diffuse uterine enlargement, sometimes leading to pelvic pressure and frequent urination. The severity of symptoms correlates roughly with the extent of disease (Benson and Sneed, 1958; Bird *et al.*, 1972; Kim *et al.*, 2004). Adenomyosis is difficult to distinguish clinically from uterine leiomyoma, since many symptoms of these two conditions are similar. Further, adenomyosis and leiomyoma are not easily distinguishable on ultrasound, and magnetic resonance imaging (MRI) is currently regarded as the best imaging tool for the differential diagnosis (Byun *et al.*, 1999; Reinhold *et al.*, 1999). However, women who present with symptoms characteristic of leiomyoma are not routinely evaluated with this relatively costly imaging modality.

Hysterectomy can be the definitive treatment for both diseases in some women who are not intent on preserving their

uteri (Stewart, 2001; Ascher *et al.*, 2003); however, the differential diagnosis between adenomyosis and leiomyoma can be important in patients who either have not completed forming families or do not wish to lose their uterus. Conservative myomectomy can be performed on most leiomyomas, but because of ill-defined endometrial–myometrial boundaries, local excision of adenomyotic lesions while preserving fertility can be problematic (Wood, 1998). Even when feasible, conservative surgery can result in fibrotic scars and sutures in surrounding healthy tissue, which can negatively affect future fertility (Wood, 1998). Therefore, alternative conservative treatments for adenomyosis with the potential to preserve fertility are being investigated (Kim *et al.*, 2004).

Magnetic resonance-guided focused ultrasound surgery (MRgFUS) has been used effectively for the non-invasive ablation of pathologic tissue (Stewart *et al.*, 2003; Tempny *et al.*, 2003). We have used MRgFUS successfully over the past years for the conservative treatment of uterine leiomyomas, without damage to healthy myometrium and without major patient morbidity (Stewart *et al.*, 2003). Owing to the accuracy and precision of this technique, we hypothesized that

MRgFUS could also treat adenomyosis successfully without deleterious effects on the surrounding myometrium and on subsequent fertility. This hypothesis was also based on our experience in some patients with combined disease, in whom we have successfully ablated both leiomyomatous and adenomyotic lesions.

### Case report

The patient participated in an ongoing study designed to examine the course of pregnancy in women who wished to conceive and carry an infant to term following MRgFUS treatment for benign uterine lesions. Patients aged 22–40 years with clinically symptomatic uterine disease who chose to avoid uterine surgery were enrolled in this study, which was approved by the ethical review board at Sheba Medical Center, Tel Hashomer, Israel.

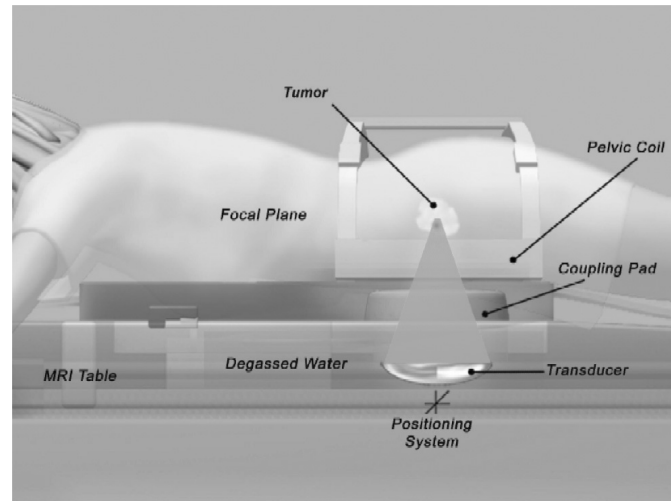
We have prior experience in using MRgFUS for the treatment of uterine fibroids in 700 women who had completed their families. In those patients, MRgFUS treatment safely and effectively coagulated leiomyomatous tissue, leading to cell death and necrosis at the target, while leaving the surrounding myometrium and uterine walls healthy and undamaged (Stewart *et al.*, 2003; Tempny *et al.*, 2003) (unpublished results).

MRgFUS is performed with the ExAblate 2000 system (InSightec, Haifa, Israel), fully integrated with the Signa 1.5 T MRI system (General Electric, Milwaukee, WI, USA). The focused ultrasound surgery (FUS) system generates a high-intensity acoustic beam that is focused on a precise target to cause thermal coagulation. Magnetic resonance (MR) guidance enables accurate target specification, directs the acoustic beam to the target and produces real-time temperature maps of treated areas, enabling adjustments to both the dose and the target during treatment.

Throughout the treatment planning and procedure, the woman lies prone on the patient table, within the MR scanner, with her abdomen coupled to a gel pad. The gel pad and a focused piezoelectric 120-mm diameter transducer array operating at frequencies from 1.0 to 1.5 MHz are located within a water bath in the MRI patient table (Figure 1).

Coronal, sagittal and axial T2-weighted MR images are obtained to localize and define the target area. The ExAblate system computes the optimal treatment parameters. Initially, a very low energy acoustic signal (sonication) is directed to the target, generating a subtle, non-destructive, temperature elevation in the tissue. An MR thermal map detects the location and confirms registration accuracy or enables the user to adjust the treatment plan as necessary.

During treatment, the FUS system performs real-time thermal imaging of the treatment area based on proton resonance frequency shift that results from tissue heating. Treatment parameters can be adjusted between sonications based on image feedback. Each sonication creates an elongated elliptical focus of high temperature (60–80°C), resulting in tissue necrosis. In an earlier study, we examined the uteri of women who went on to hysterectomy after MRgFUS. Treated tissue showed a series of distinct lesions that were visible macroscopically. Microscopic analysis revealed complete coagulation necrosis within the target (Stewart *et al.*, 2003).



**Figure 1.** Magnetic resonance imaging (MRI)-guided focused ultrasound surgery. A woman is shown lying prone on the patient table, within the MR scanner. Her abdomen is coupled to a gel pad, which contains water bath and a focused piezoelectric 120-mm diameter transducer array operating at frequencies from 1.0 to 1.5 MHz. Ultrasound waves are focused on a series of foci within the target area. MRI guides and verifies tumour ablation during the procedure.

MRgFUS is administered on an outpatient basis with conscious sedation. The procedure generally requires 2–3 h. Patients are observed for 1–2 h following treatment and discharged home with a companion.

Upon admission to the study, the patient was 36 years old, married and had one child. She had no abnormal medical history and no history of miscarriage or any prior invasive uterine procedures. The course of her previous pregnancy and delivery was normal.

Her primary symptoms were prolonged and irregular menstrual bleeding, menometrorrhagia, abdominal distention and chronic fatigue. Her gynaecologist diagnosed a uterine leiomyoma based on an enlarged uterus and ultrasonographic imaging of a circumscribed uterine tumour. Owing to the patient's menometrorrhagia, which limited her ability to have timely intercourse and to conceive, her physician recommended that she undergo conservative myomectomy. While looking into myomectomy, she learned of our MRgFUS programme. She wished to bear at least one more child and thus sought to avoid an invasive surgical procedure with attendant possible side effects and complications. At the first appointment, we determined that she was generally healthy, with no abnormal medical history. On clinical examination, the uterus was enlarged to about 14 weeks' gestational age. Her infertility workup did not demonstrate any pathological finding except for an enlarged uterus. Pelvic ultrasound revealed a single posterior uterine wall mass (5.6 cm × 7.2 cm), consistent with leiomyoma. After adequate informed consent, the patient decided to enrol in the MRgFUS study rather than undergo myomectomy, and we performed the first series of MR images for treatment planning purposes.

On T2-weighted MRI, a round lesion was seen. This lesion was hypointense compared to the uterine wall, with small hyperintense granulation, similar in appearance and consecutive

with the endometrial junctional zone, and located in the posterior wall of an anteфлекted uterus. Its maximal dimensions on MRI were 6.5 cm × 4.9 cm × 4.8 cm, and its volume, measured using the sum-of-slices method, was 84 cm<sup>3</sup>. Because of the lesion's MRI appearance, we revised the diagnosis from uterine leiomyoma to focal uterine adenomyosis. On the basis of our previous experience with adenomyotic uterine lesions, and after additional informed consent of the patient, we proceeded with MRgFUS (Figure 2A).

During MRgFUS treatment, a significant portion of the lesion was ablated. At the end of treatment, a non-perfused volume of 33 cm<sup>3</sup> was measured using the sum-of-slice method, and based on MRI, T1-weighted gadolinium contrast-enhanced images were acquired immediately following treatment (Figure 2B).

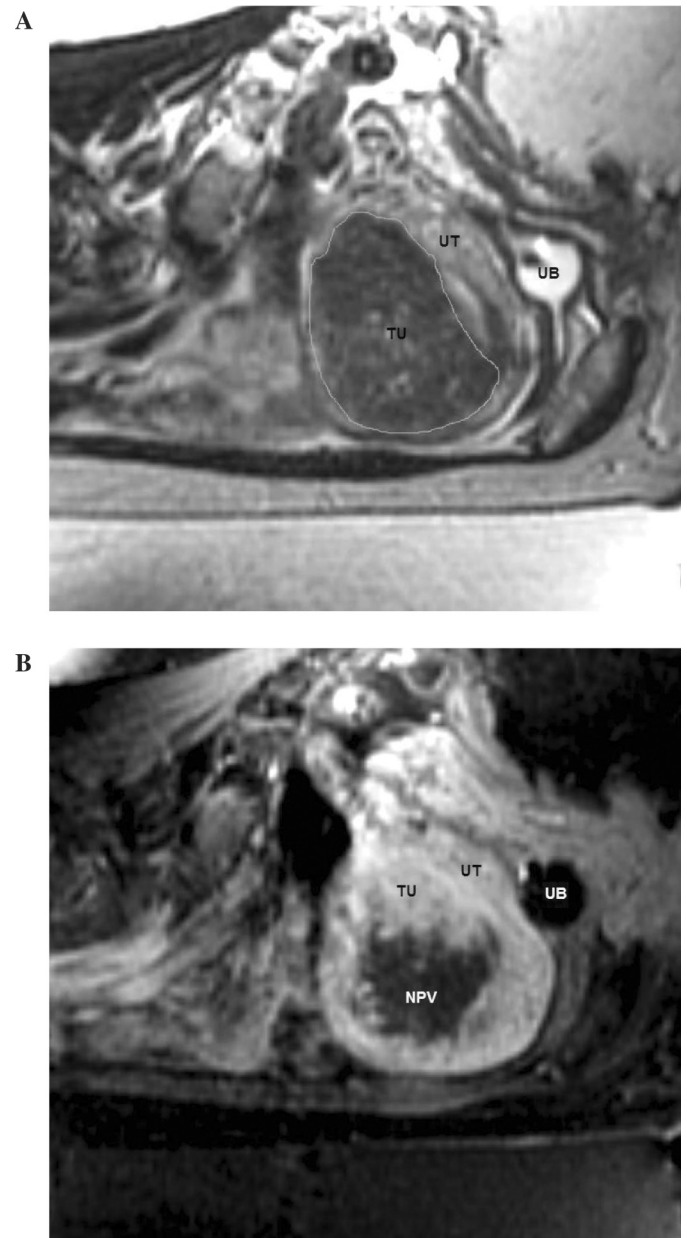
The patient completed MRgFUS with no complications. She graded the level of pain during treatment as moderate and reported little or no discomfort after being discharged. During the weeks following treatment, she experienced a significant reduction in menometrorrhagia. Six weeks after MRgFUS, the adenomyotic tumour showed a marked decrease in size to 3.5 cm × 4.3 cm on vaginal ultrasound.

Three menstrual cycles after MRgFUS, the patient conceived spontaneously. The course of her pregnancy was uneventful. Repeated ultrasound scans demonstrated normal fetal development, normal placental insertion in the posterior uterine wall and normal uterine anatomy. She gave birth to a full-term, 3.050 kg, healthy baby girl after an uneventful labour and vaginal delivery. Following delivery of the newborn, placental separation was delayed. Manual extraction of the placenta and manual uterine examination and revision were performed. The uterine walls were judged to be intact and without any major structural abnormality. The post-partum course was uneventful, and the patient returned to her daily routine without major complaints.

## Discussion

This report describes a successful pregnancy and delivery after MRgFUS treatment of an adenomyotic uterus. This case highlights the difficult diagnostic and therapeutic considerations in the treatment of adenomyosis in women who wish to preserve their uterus.

The 'benign invasion of endometrium into myometrium' that occurs in adenomyosis can lead to enlargement of the uterus and reactive hyperplasia and hypertrophy of the neighbouring myometrium (Bird *et al.*, 1972). Resulting clinical signs and symptoms can overlap with those seen with uterine leiomyomas, and the differential diagnosis between these conditions is often difficult (Ascher *et al.*, 2003). The prevalence of adenomyosis in hysterectomy specimens can range from 10 to 18% (Benson and Sneed, 1958; Owolabi and Strickler, 1977; Bergholt *et al.*, 2001). In histopathological reports, roughly one-third of adenomyosis patients have focal lesions with clearly demarcated borders, while most patients have diffuse lesions characterized by ill-defined endometrial-myometrial boundaries (Bergholt *et al.*, 2001; Byun *et al.*, 1999). Up to 80% of adenomyotic uteri contain associated pathologies, and uterine adenomyosis can coexist with leiomyomas in 35–55%



**Figure 2.** Magnetic resonance imaging (MRI) of the pelvis before (A) and immediately after (B) magnetic resonance-guided focused ultrasound surgery (MRgFUS) treatment. (A) Sagittal view of a pelvic T2-weighted MR image in this patient before the start of the MRgFUS treatment. Note the uterus (UT), urinary bladder with catheter *in situ* (UB) and uterine tumour (TU). (B) Gadolinium contrast-enhanced sagittal T1-weighted MR image immediately after MRgFUS. Note the uterus (UT), urinary bladder with catheter *in situ* (UB) and uterine tumour (TU). A significant part of the tumour is hypointense (dark area; NPV), showing successful ablation of the tissue.

of cases (Ferenczy, 1998). The correct diagnosis of adenomyosis is very often made only post-operatively, on pathological examination of a 'leiomyomatic' uterus (Owolabi and Strickler, 1977). Today, MRI is the most accurate radiologic modality for differentiating leiomyomas and adenomyosis pre-operatively (Ascher *et al.*, 1994, 2003; Arnold *et al.*, 1995); however, MRI is not routinely used for the evaluation of these patients.

A correct differential diagnosis can be critical, because the optimal treatment modalities for these two entities may differ. Specifically, in women with symptomatic leiomyomas, uterine-conserving surgical therapy is well established, whereas hysterectomy remains the treatment of choice for debilitating adenomyosis (Ascher *et al.*, 2003). In contrast to uterine leiomyoma, adenomyosis is not demarcated from the adjacent myometrium by a capsule. Difficulty in defining the location and the extent of adenomyosis often makes it difficult to determine the feasibility and extent of complete excision when attempting to preserve the uterus (Wood, 1998). Women with diffuse disease are often not considered as candidates for conservative surgery (Outwater *et al.*, 1998; Wood, 1998). Removal of adjacent healthy myometrium may increase the risk of bleeding and extensive damage to the uterine wall and could negatively affect the tensile strength of the uterus during pregnancy and labour and, thus, the ability of the uterus to carry future pregnancies safely to term (Wood, 1998).

In addition, myomectomy is a surgical procedure that requires anaesthesia, is associated with significant intra-operative complications (bleeding, need for blood transfusions, etc.) and may require a long recovery period. Patients can experience both short-term and long-term post-operative complications (pyrexia, infections, abdominal adhesions, uterine rupture, pregnancy complications, etc.) (Olufowobi *et al.*, 2004). The relevance of myomectomy in the management of the infertile woman remains controversial (Donnez and Jadoul, 2002).

Alternatives to conservative myomectomy, such as uterine artery embolization (UAE), are being sought (Razavi *et al.*, 2003). Possible ovarian damage (Payne *et al.*, 2002; Payne and Haney, 2003; Tropeano *et al.*, 2003) and pregnancy complications (Goldberg *et al.*, 2004) after UAE for uterine leiomyomas have led to debate over the safety of widespread use of this alternative.

The primary clinical diagnosis in our patient was uterine leiomyoma. She suffered from irregular bleeding episodes that prevented her from conceiving. She sought alternatives to her scheduled conservative myomectomy, learned of our MRgFUS programme and chose to enrol in our study. Her diagnosis was revised to adenomyosis on the basis of our routine MRI pre-treatment planning study.

MRgFUS is a non-invasive technique for the ablation of soft tissue that offers a new approach to conservative non-invasive uterine surgery (Stewart *et al.*, 2003). Sequential ultrasound beams are precisely focused on a series of small foci within the larger target volume to locally heat tissue under real-time MR guidance and control, causing thermal coagulation and subsequent tissue necrosis in a precisely defined area. MRgFUS is performed as an outpatient procedure with conscious sedation and without additional need for medication. Patients report minimum-to-moderate levels of pain during and after the procedure and can return immediately to their daily routine.

We have seen significant reduction in the size of leiomyomata and marked reduction in symptoms (Stewart *et al.*, 2003) following treatment with MRgFUS. MRI follow-up studies have shown that adjacent and distant healthy myometrium and uterine walls are preserved; only the targeted pathological tissue is destroyed (Tempany *et al.*, 2003).

In this patient, as in previous patients, sonographic ablation of the uterine tumour was achieved without any complications or side effects. The patient was discharged for ambulatory follow-up approximately 2 h after the procedure. She conceived immediately after our 3-month recommended 'waiting period'. During these months, there was a marked reduction in the size of her adenomyotic lesion, and she experienced a significant lessening of her bleeding episodes. Her previous infertility was apparently caused by the irregular bleeding episodes, which may have prevented timely intercourse, adequate conception and implantation. Once the irregular bleeding problem was corrected, her fertility was immediately restored.

Her pregnancy and delivery were not negatively affected by MRgFUS procedure, which occurred only 3 months before conception. The remnants of the adenomyotic tumour were seen on ultrasonographic evaluations during her pregnancy. No major structural abnormality was detected on post-partum manual exploration of the uterine cavity. She gave birth to a healthy, full-term daughter following normal vaginal delivery.

## Conclusion

This report describes the first case of a successful pre-conceptual treatment of uterine adenomyosis with MRgFUS in an infertile woman. Further, it highlights the difficult diagnostic and therapeutic considerations in the pre-conceptual treatment of adenomyosis. MRgFUS is a novel, non-invasive technique that allows the very accurate destruction of intracorporeal solid tumours, without damage to the outer layers of the body. In our patient, the ensuing pregnancy was achieved quickly after treatment, progressed normally and ended successfully at term. However, only future large studies will be able to ascertain the safety of MRgFUS as a pre-conceptual treatment for uterine benign tumours in general and for adenomyosis in particular.

## Acknowledgements

The authors thank Mrs Shifra Fraifeld for her editorial work in the preparation of this manuscript.

## References

- Arnold LL, Ascher SM, Schrufer JJ and Simon JA (1995) The nonsurgical diagnosis of adenomyosis. *Obstet Gynecol* 86,461–465.
- Ascher SM, Arnold LL, Patt RH, Schrufer JJ, Bagley AS, Semelka RC, Zeman RK and Simon JA (1994) Adenomyosis: prospective comparison of MR imaging and transvaginal sonography. *Radiology* 190,803–806.
- Ascher SM, Jha RC and Reinhold C (2003) Benign myometrial conditions: leiomyomas and adenomyosis. *Top Magn Reson Imaging* 14,281–304.
- Benson RC and Sneed VD (1958) Adenomyosis: a reappraisal of symptomatology. *Am J Obstet Gynecol* 76,1044–1057; discussion 1057–1061.
- Bergholt T, Eriksen L, Berendt N, Jacobsen M and Hertz JB (2001) Prevalence and risk factors of adenomyosis at hysterectomy. *Hum Reprod* 16,2418–2421.
- Bird CC, McElin TW and Manalo-Estrella P (1972) The elusive adenomyosis of the uterus—revisited. *Am J Obstet Gynecol* 112,583–593.
- Byun JY, Kim SE, Choi BG, Ko GY, Jung SE and Choi KH (1999) Diffuse and focal adenomyosis: MR imaging findings. *Radiographics* 19 Spec No,S161–S170.
- Donnez J and Jadoul P (2002) What are the implications of myomas on fertility? A need for a debate? *Hum Reprod* 17,1424–1430.
- Ferenczy A (1998) Pathophysiology of adenomyosis. *Hum Reprod Update* 4,312–322.
- Goldberg J, Pereira L, Berghella V, Diamond J, Darai E, Seiner P and Seracchioli R (2004) Pregnancy outcomes after treatment for fibromyomata:

- uterine artery embolization versus laparoscopic myomectomy. *Am J Obstet Gynecol* 191,18–21.
- Kim MD, Won JW, Lee DY and Ahn CS (2004) Uterine artery embolization for adenomyosis without fibroids. *Clin Radiol* 59,520–526.
- Olufowobi O, Sharif K, Papaionnou S, Neelakantan D, Mohammed H and Afnan M (2004) Are the anticipated benefits of myomectomy achieved in women of reproductive age? A 5-year review of the results at a UK tertiary hospital. *J Obstet Gynaecol* 24,434–440.
- Ota H, Igarashi S, Hatazawa J and Tanaka T (1998) Is adenomyosis an immune disease? *Hum Reprod Update* 4,360–367.
- Outwater EK, Siegelman ES and Van Deerlin V (1998) Adenomyosis: current concepts and imaging considerations. *AJR Am J Roentgenol* 170,437–441.
- Owolabi TO and Strickler RC (1977) Adenomyosis: a neglected diagnosis. *Obstet Gynecol* 50,424–427.
- Payne JF and Haney AF (2003) Serious complications of uterine artery embolization for conservative treatment of fibroids. *Fertil Steril* 79,128–131.
- Payne JF, Robboy SJ and Haney AF (2002) Embolic microspheres within ovarian arterial vasculature after uterine artery embolization. *Obstet Gynecol* 100,883–886.
- Razavi MK, Hwang G, Jahed A, Modanloo S and Chen B (2003) Abdominal myomectomy versus uterine fibroid embolization in the treatment of symptomatic uterine leiomyomas. *AJR Am J Roentgenol* 180,1571–1575.
- Reinhold C, Tafazoli F, Mehio A, Wang L, Atri M, Siegelman ES and Rohoman L (1999) Uterine adenomyosis: endovaginal US and MR imaging features with histopathologic correlation. *Radiographics* 19 Spec No, S147–S160.
- Stewart EA (2001) Uterine fibroids. *Lancet* 357,293–298.
- Stewart EA, Gedroyc WM, Tempany CM, Quade BJ, Inbar Y, Ehrenstein T, Shushan A, Hindley JT, Goldin RD, David M *et al.* (2003) Focused ultrasound treatment of uterine fibroid tumors: safety and feasibility of a noninvasive thermoablative technique. *Am J Obstet Gynecol* 189,48–54.
- Tempany CM, Stewart EA, McDannold N, Quade BJ, Jolesz FA and Hynynen K (2003) MR imaging-guided focused ultrasound surgery of uterine leiomyomas: a feasibility study. *Radiology* 226,897–905.
- Tropeano G, Litwicka K, Di Stasi C, Romano D and Mancuso S (2003) Permanent amenorrhea associated with endometrial atrophy after uterine artery embolization for symptomatic uterine fibroids. *Fertil Steril* 79,132–135.
- Wood C (1998) Surgical and medical treatment of adenomyosis. *Hum Reprod Update* 4,323–336.

*Submitted on December 5, 2004; resubmitted on September 7, 2005; accepted on September 7, 2005*